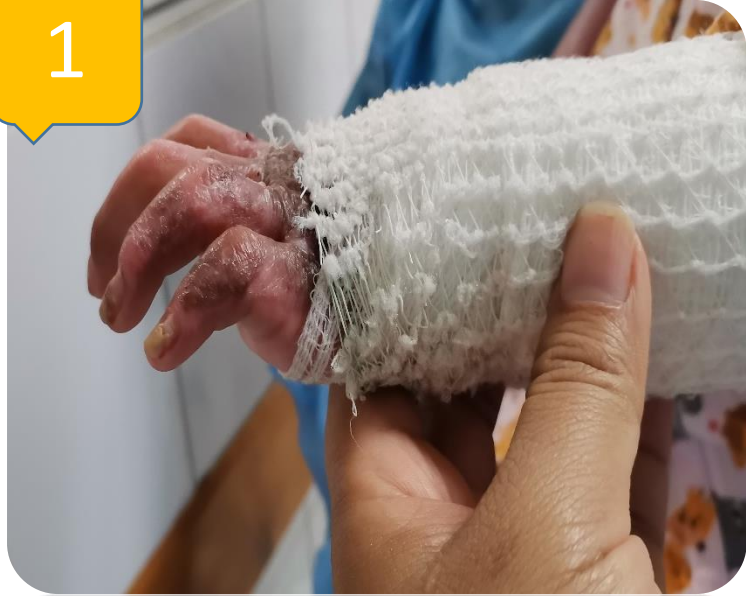

RESULT OF THE APPLICATION OF SERIAL PLASTER IN CONTRACTED HAND

Author: Amparo Hidalgo PT

DORSAL BURN SCARS

1

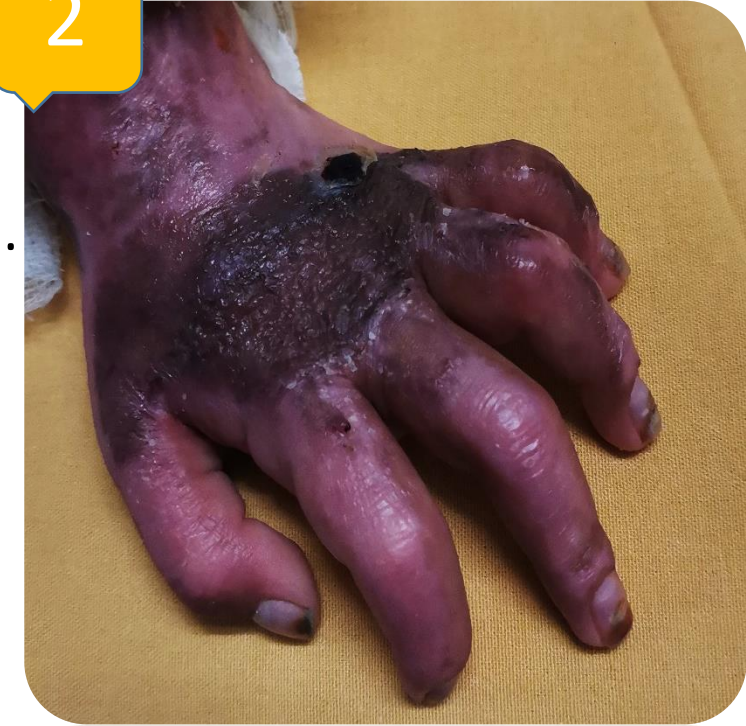

OBJETIVE: To demonstrate the efficacy of the Serial Plaster technique in the treatment of burned hand contractures.

CASES: Retrospective study of 33 cases attending the outpatient for Burn Children Clinic between 2018 to date.

RESULT: 19 cases (58%) a full functionality was recovered. 14 cases that correspond to (42%) presented a residual contracture that required surgery, and rehabilitaci3n therapy

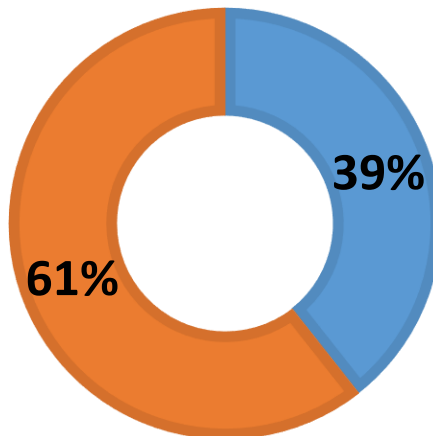
2



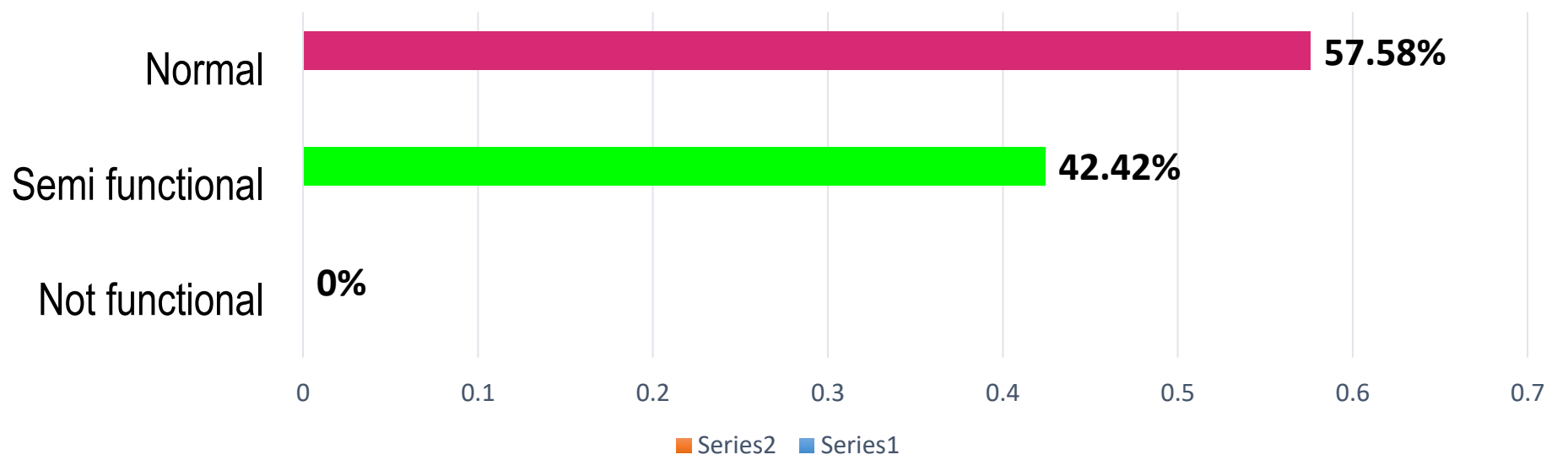
Reapplication every week for 5 or 6 times

REQUIRED SURGERY

■ MINOR SURGERY ■ NO SURGERY



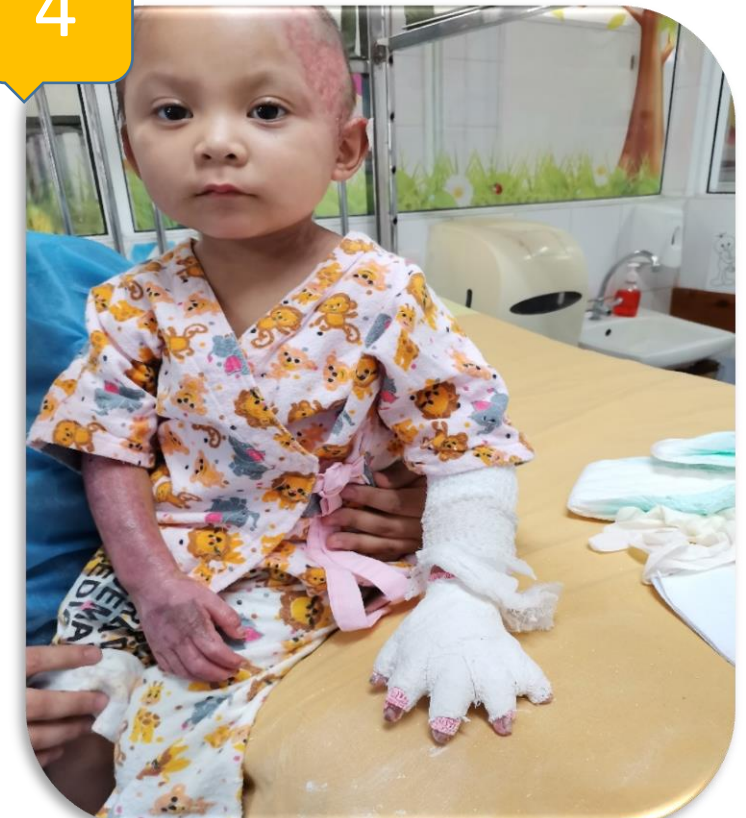FUNCTIONALITY



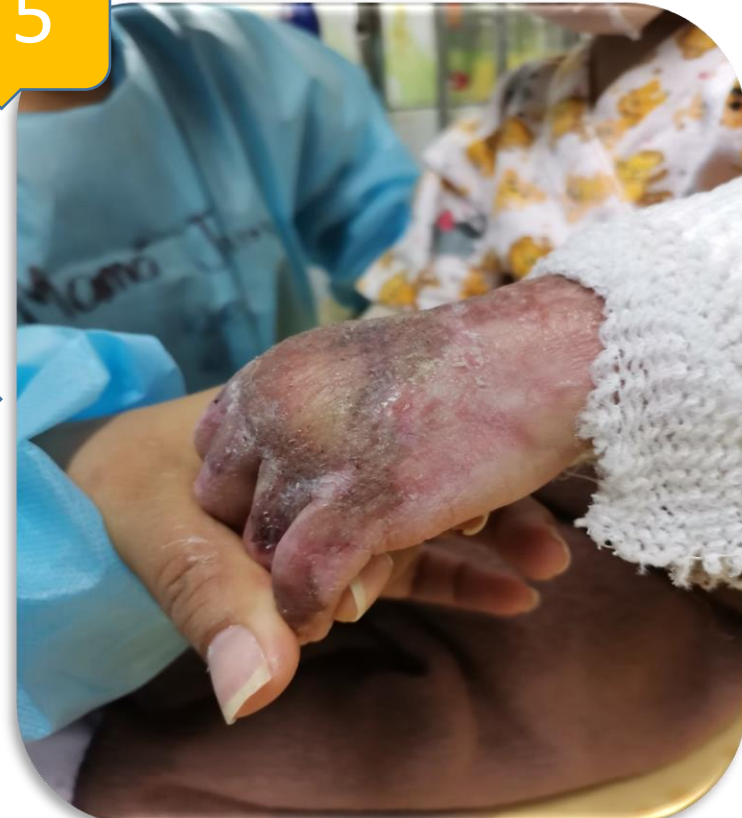3



4



5



6

